

An Intelligent Mobile-Based Automatic Diagnostic System to Identify Retinal Diseases using Mathematical Morphological Operations

Mohamed Omar, Alamgir Hossain, Li Zhang and Hubert Shum
Computational Intelligence Group, Department of Computer Science and Digital Technologies
Northumbria University, Newcastle upon Tyne, NE2 1XE, UK
e-mail: {mohamed.omar, alamgir.hossain, li.zhang, hubert.shum }@northumbria.ac.uk

Abstract— Diabetic retinopathy is considered in terms of the presence of exudates which cause vision loss in the areas affected. This study targets the development of an intelligent mobile-based automatic diagnosis integrated with a microscopic lens to identify retinal diseases at initial stage at any time or place. Exudate detection is a significant step in order obtaining an early diagnosis of diabetic retinopathy, and if they are segmented accurately, laser treatment can be applied effectively. Consequently, precise segmentation is the fundamental step in exudate extraction. This paper proposes a technique for exudate segmentation in colour retinal images using morphological operations. In this method, after pre-processing, the optic disc and blood vessels are isolated from the retinal image. Exudates are then segmented by a combination of morphological operations such as the modified regionprops function and a reconstruction technique. The proposed technique is verified against the DIARETDB1 database and achieves 85.39% sensitivity. The proposed technique achieves better exudate detection results in terms of sensitivity than other recent methods reported in the literature. In future work, our system will be deployed to a mobile platform to allow efficient and instant diagnosis.

Keywords— Diabetic Retinopathy; Mobile Technology; Exudates; Optic Disc; Morphological Operation.

I. INTRODUCTION

Diabetes is a common cause of eye disease and can have the major effect of blindness. Patients' sight can be affected by cataracts and glaucoma caused by diabetes. Most significantly, when small blood vessels in the retina are damaged, fluid forms on the retina causing features such as exudates, a condition popularly known as "diabetic retinopathy" (DR) [1]. The major symptom of diabetic retinopathy is the presence of exudates. These cause yellow lesions of different shapes and sizes which are major signs of vision loss in non-proliferative forms of DR. According to the WHO, diabetes affects more than 347 million people worldwide, particularly in developing countries [3]. More than 75% of patients who have had diabetes for more than 20 years will have some form of DR. Hence, the detection of exudates is necessary for the early diagnosis and treatment of DR in order to preserve vision [4].

The RGB image of the retina has three main sections, as displayed in Figure 1. The optic disc is the point of exit of the optic nerve and the fovea describes the centre of the macula of

the retina, and this region gives most acute. The third section consists of the exudates as explained previously [5].

Morphological operations and reconstruction operations are well-known technical tools to differentiate images of exudates into different types. Moreover, these operations are also capable of distinguishing between extremely complex images with overlapping or extraction components and they have been used in many research fields such as medicine, biomedicine, computer vision, remote sensing, video coding and many more. Although there has been extensive research on exudate segmentation, it faces various challenges such as the presence of noise, textured regions, low contrast, overlapping, and the size and high intensity of the images [6].

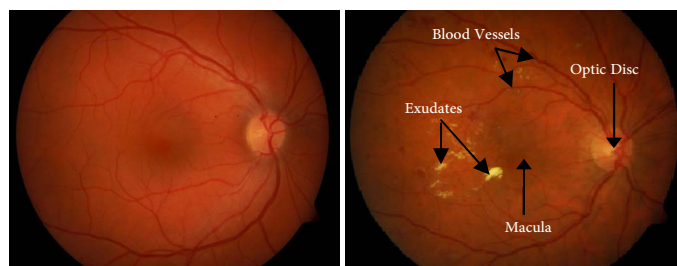


Fig. 1. Fundus images for normal (left) and abnormal (right) retina.

Computerized screening systems have been developed to classify normal and abnormal retinal images [7]. The automatic detection of retinal abnormalities has shown promising results and can assist doctors in better decision making [8]. Therefore, retinal disease detection based on mobile technology using a microscopic lens attached to a smartphone can be operated efficiently for the early detection of DR [2, 9].

However, research has shown that exudate segmentation is a challenging problem due to the variability of illumination. In particular, the optic disc and exudates show great similarities in terms of high levels of variation in the intensity band of colour fundus images. Thus, the detection of exudates is a challenging task but is also a very significant task in DR diagnosis.

II. RELEVANT WORK

Sopharak et al. [10] proposed an algorithm based on the enhancement of contrast in the histogram equalization of the

RGB fundus image. Vessels were eliminated by using a closing operator. Afterwards the optic disc is removed by applying an entropy feature method. A morphological reconstruction using a dilation operation was used to segment exudate areas.

Welfer et al. [5] applied mathematical morphology using the perceptually uniform Luv of colour space for lightness L, where the variations of intensity in the L band were slightly less than in the retinal fundus image. They also applied morphological operations based on top-hat techniques, local minima and thresholding techniques to detect the exudate regions. Eadgahi et al. [11] also proposed a method based on morphological operations. The green component was firstly taken from retinal images in a pre-processing stage. Then, the optic disc and blood vessels were eliminated. Finally, morphological operations, for instance top-hat/bottom-hat and reconstruction operations were combined to segment the exudate regions.

Youssef et al. [12] proposed a method to detect all areas of yellow colour, the highest intensities, high contrast and the contours. Firstly, the optic disc and vessels were eliminated from the image obtained from edge detection, which gave primary estimation of the exudate regions. Then a method of morphological reconstruction was used to identify the exudates in the final stage. Sanchez et al. [13], masked out and localized the optic disc using regional maxima and Hough transform algorithms. Then the exudates were segmented by applying morphological operations. Kumari et al. Ravishankar et al. [14] developed an approach to extract the blood vessels of different thickness using opening and closing operations. Exudates were detected using opening and closing operations with different sizes of structuring elements (SEs). The blood vessel image is subtracted from the image of detected exudates to obtain the optic disc region. Meanwhile the optic disc and the exudates have similar structures in term of shapes and high gray levels; therefore, the optic disc is removed in most methods in order to reduce false positives.

Retinal image acquisition using a low-cost fundus camera is the most widely used method. However, the segmentation of such bright lesions and subsequent follow-up operations are not easy. This is due to: 1) the presence of anatomical structures with highly correlated pixels from the lesion; 2) illumination variability; and 3) the movement of the eye during examinations of the patient.

Therefore, this paper proposes an accurate and efficient algorithm to extract all of the exudates in RGB images. The proposal is based on morphological and reconstruction operations and it has two sections: (1) blood vessel elimination and exudate extraction; and (2) optic disc detection, which is used to differentiate it from the exudate area.

Although the techniques previously presented [11-14] have provided methods to identify exudates, the authors did not clearly state how the optic disc is eliminated when in different locations. In our contrast, suggested method indicates how optic discs are isolated in different locations.

III. MATERIALS

The RGB retinal images which were used in this paper were acquired from the DIAREDB1 database [15], which contains 89 RGB images of pixel size 1500x1152. The RGB fundus images consist of different lesions, for instance exudate regions, microaneurysms and hemorrhages. The database also contains the ground truth images which were used to test our algorithm.

IV. METHODOLOGY

A combination of morphological operations is used to detect the exudates in this proposed method. At this current stage of the work, the exudates are detected using mathematical morphology and reconstruction techniques. An important step in the extraction process is to remove prominent structures in the retina, such as blood vessels and the optic disc. This stage can be separated into three steps: pre-processing, optic disc removal and exudate extraction. In pre-processing, the RGB fundus image is transformed into the HSI image space. Afterwards, the technique of median filtering is performed on the intensity band (I-band) in order to suppress noise [16]. Next, the contrast limited adaptive histogram equalization technique is used so as to enhance the contrast in order to avoid over-saturation in the identical regions in the image of the retina [17]. Noise is removed by applying a Gaussian function technique. The results of these pre-processing operations are shown in Fig 2. After that, the RGB image is transformed into the HSI space and the intensity band is used for further processing [18]. Exudates and the optic disc have similarities and show high intensity values in the intensity band, and as a result optic disc elimination is needed. Also it is well known that the object with the largest circular or largest oval shape in the RGB image will be the optic disc (OD) [10].

A. Optic Disc Isolation

Firstly, the technique of a closing operation with a structuring element for a flat disc is used with the pre-processed image I_1 [19]. A thresholding technique is applied to the image obtained to convert it to a binary image. All of the connected objects from the new binary image Ω of C_i are generated by Equation 1:

$$\Omega = \bigcup_{k \in m} C_k, C_i \cap C_j = 0, \quad \forall i, j \in m, i \neq j \quad (1)$$

where k is the number of connected objects and $m = 1, 2, 3, \dots$. If the object has a circular shape and the largest number of pixels among C_i it contains the optic disc, and for that reason the optic disc has to be extracted to separate it from other regions in the RGB image. If the largest connected object is R_i , the compactness C of R_i is measured using Equation 2:

$$C(R_i) = 4\pi \frac{A(R_i)}{P^2(R_i)} \quad (2)$$

where $A(Ri)$ is the total number of pixels in area i and $P(Ri)$ is the total number of pixels around Ri . The thresholding technique is used to measure compactness by applying Nilblack's method and the regionprops function separately.

With this technique, the optic disc is isolated before exudate detection, since both types of objects are of similar intensity and colour. Figure 3(a) displays the image obtained after the closing operation technique was used with the structuring element of a flat disc in order to isolate the blood vessels. The largest circular object in the RGB image is the optic disc, and for that reason it is extracted. For thresholding, 1.6 is given as a weight using the Nilblack's technique and the region of the optic disc is brighter than other objects in the RGB image.

The binary images are obtained as shown in Figure 3(b) and (c) after the Nilblack's method and the regionprops function have been used. Therefore, the largest connected object is considered to be the optic disc, due to it having the high value of density.

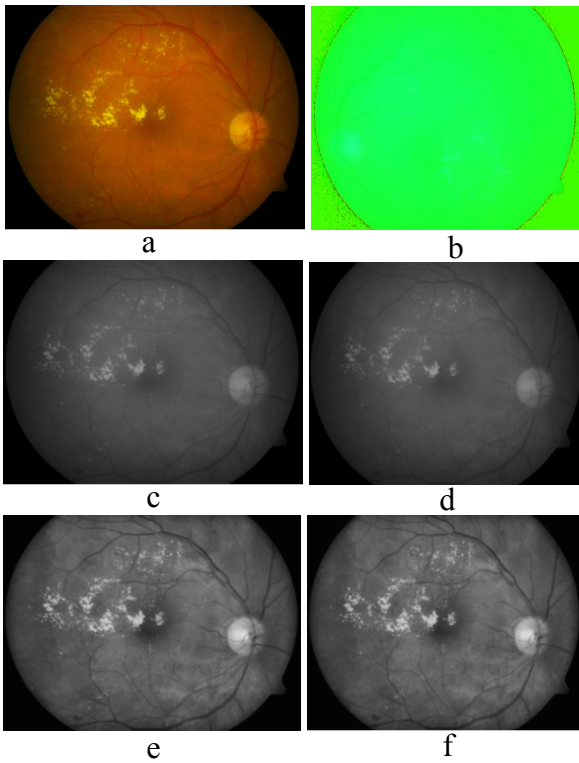


Fig. 2. Images from the pre-processing phase (I1).

- a. RGB image
- b. HSI space
- c. Image of intensity band
- d. Image after median filter is applied
- e. Adaptive histogram equalisation technique
- f. Gaussian function

In the example shown in Fig. 3(d), after applying Nilblack's technique, the resultant image displays high compactness in the large circular object.

The results of optic disc isolation in the RGB images are not always precise, and the Hough transformation technique is therefore used when the shape of the optic disc is not circular, for example, an oval.

Thus the technique of the Hough transform is not always dependable in detecting the optic disc (OD) since not all RGB images include an optic disc with a circular shape. Therefore, the optic disc is localized and detected using the modified regionprops function.

B. Exudate Detection

After that, exudates have to be extracted from the image I2 after the optic disc has been isolated. The blood vessels are removed after applying a closing operation technique with a structuring element of a flat disc to the I2 image, as both blood vessels and exudates show high values of contrast (see Figure 4(a)).

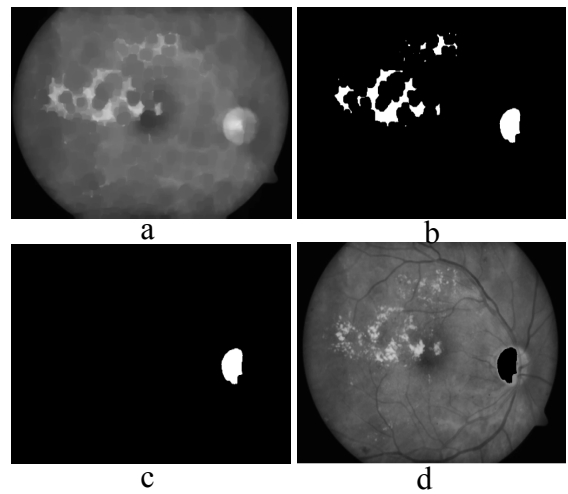


Fig. 3. Images obtained during optic disc elimination (I2).

- a. Closing operation technique
- b. Nilblack's technique is used for image thresholding
- c. Large circular object is detected using the modified regionprops function
- d. Results obtained from the pre-processed image after the optic disc is isolated

We apply the above closing operation method with a structuring element of a flat disc of a radius of 10 pixels to isolate the blood vessels with high values of contrast in the RGB images before the thresholding values are applied. The resulting image I3 is obtained after applying the standard deviation and is derived using Equation 3:

$$I_3(x) = \frac{1}{N-1} \sum_{i \in W(x)} (I_2(i) - \overline{I_3(x)})^2 \quad (3)$$

where x is a set of all pixels in a sub-window $W(x)$ with N as the number of pixels in $W(x)$, and $\overline{I_3(x)}$ is the mean of $I_3(x)$ (see Figure 4(b)). The thresholded image is obtained using the triangle method after the local contrast of the image I3 is enhanced (see Figure 4(c)).

Since the detection of exudates can be confused by the edges of both the images of certain objects and the optic disc, we use closing and opening operators to remove the image border from the thresholded image in order to obtain closely distributed exudates (see Figure 4(d)).

Afterwards, flood filling is applied to all holes (see Figure 4(e)). Since in some RGB images the optic disc is close to the borders while in others this is not the case, we use our modified regionprops function technique for the optic disc to be isolated, as shown in Figure 4(f).

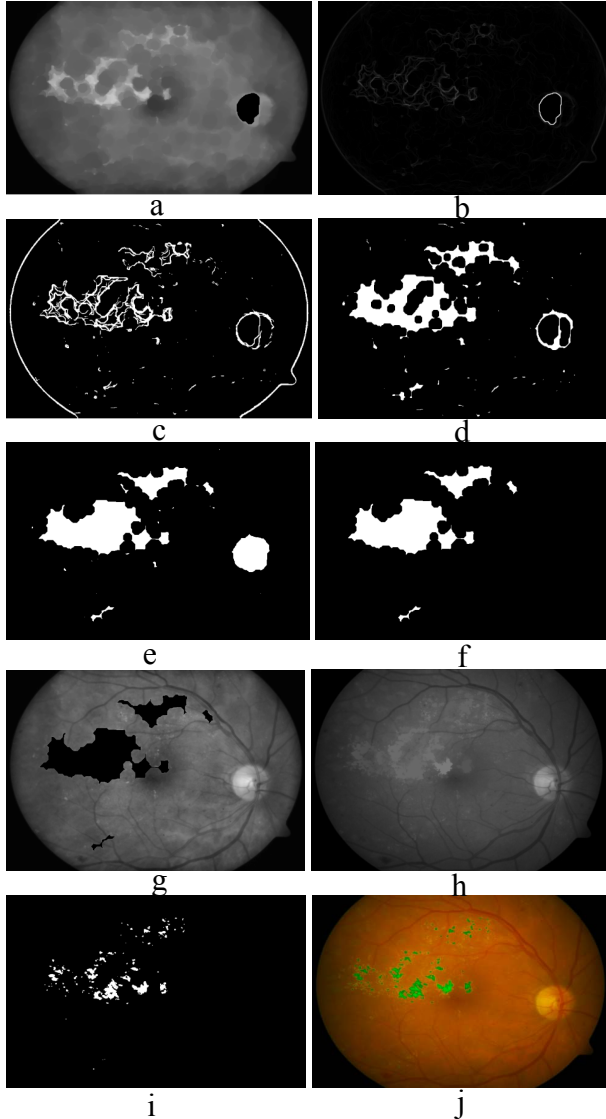


Fig. 4. Images obtained during exudate detection (13).

- a. Closing operation technique
- b. Technique of standard deviation
- c. Triangle method for thresholded image
- d. Borders removed using closing operator
- e. Holes are filled
- f. OD eliminated using modified regionprops techniques
- g. Mask of marker image
- h. Reconstructed morphological image
- i. Thresholded image
- j. Exudates obtained superimposed on original image and marked in green.

Next, a marker image mask is applied as shown in Figure 4(g) for morphological reconstruction [20]. During this process, the peaks in the marker image are dilated and eroded until the contour of the image of the marker fits below the image of the mask, as indicated in Figure 4(h). The difference between the image obtained from the earlier stage and the image of the intensity band is taken for the thresholded image. The image obtained from thresholding as shown in Figure 4(i) is superimposed on the original retinal image. Figure 4(j) shows the final output.

V. RESULTS AND DISCUSSION

In this paper, the proposed method was tested on the DIARETDB1 database in order to evaluate the system. The images used for testing have sufficient quality, illumination and variation in colour. Figure 4 shows the results of the whole procedure of exudate detection. Also, the results shown in Figure 5 reveal the advantages of the proposed algorithm. For example, even though the contrast in the image and optic disc are very weak, the algorithm still has the ability to efficiently detect the exudates. The RGB images of a size of 1500×1152 pixels are selected in order to test our proposed system.

The algorithm was evaluated by comparing our extraction results with the ground truth image database. The sensitivity measurement is used in order to evaluate classifier performance, which is the percentage of real exudate pixels detected. Sensitivity is defined using Equation 4:

$$\text{Sensitivity } y = \frac{TP}{TP + FN} \quad (4)$$

where TP is the number of exudate pixels correctly detected (true positive), and the FN is the number of exudate pixels that are not detected (false negative). The results achieved are summarized in Table I comparing our proposed technique and other recent methods reported in the literature. All of the approaches shown in the table used morphological operations and were tested on RGB images from the DIARETDB1 database.

TABLE I. COMPARISON OF EXUDATE DETECTION TECHNIQUES USING THE DIARETDB1 DATABASE

Method	Average sensitivity
Sopharak, et al [10]	43.48 %
Welfer, et al [5]	70.48 %
Eadgahi, et al [11]	78.28 %
Proposed method	85.39 %

The average sensitivity achieved for our proposed technique is 85.39% as shown in Table I, whereas the average sensitivities of the other methods ranged from 43.48% to 78.28%. This shows that exudate detection using our method has significantly improved upon the results achieved using other methods in terms of sensitivity.

VI. CONCLUSION

This paper has presented an accurate and efficient algorithm to extract all of the exudates in RGB images. At this stage, the intensity band (I-band) of HSI space was used. Due to the noise present in RGB images, several techniques for preprocessing steps are used for the suppression of noise and the enhancement of structures in order to match regions displaying high values of contrast.

The fully automatic technique was applied to a database of retinal images available in the public domain, without needing to change any parameters during algorithm execution. The experimental results using DIARETDB1 database images indicate that the proposed technique can work with very low intensity values of images and significantly enhances the results of exudate detection in terms of sensitivity when compared with other approaches available in the literature. Also, the method presented for optic disc detection using our modified regionprops function technique enhances the accuracy of exudate detection.

In future work, we will thus focus on detecting soft exudates and soft drusen with very low intensity values and subsequent feature extraction and selection, along with integration with a neural network classifier in order to achieve better results for disease detection. We will also deploy the overall system to a mobile platform to further promote instant and early disease diagnosis. Furthermore, energy efficiency algorithms will also be considered for the deployment of our application to a mobile platform [21].

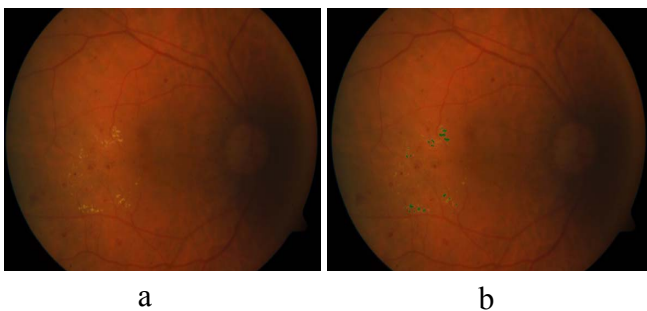


Fig. 5. Original image (a); and the exudates obtained marked in green superimposed on the original low quality image (b).

REFERENCES

- [1] A. Bhuiyan, B. Nath, and K. Ramamohanarao, "Detection and classification of bifurcation and branch points on retinal vascular network," *International Conference on Digital Image Computing Techniques and Applications (DICTA)*, 8, 3-5 Dec. 2012.
- [2] D. Ning, and Y. Li, "Automated identification of diabetic retinopathy stages using support vector machine," *32nd Chinese Control Conference (CCC)*, 3882,3886, 26-28 July 2013.
- [3] World Health Organisation "WHO-Blindness-Prevention" [Online]. Available: [http://www.who.int/blindness/Prevention of Blindness from Diabetes MeUitus-with-cover-small.pdf](http://www.who.int/blindness/Prevention%20of%20Blindness%20from%20Diabetes%20MeUitus-with-cover-small.pdf). Accessed on 1st of March 2014.
- [4] M. Niemeijer, M. D. Abrámoff, and B. Van Ginneken, "Segmentation of the optic disc, macula and vascular arch in fundus photographs." *IEEE Transactions on Medical Imaging*, 26, no. 1 (2007): 116-127.
- [5] D. Welfer, J. Scharcanski, and D. Ruschel Marinho, "A coarse-to-fine strategy for automatically detecting exudates in color eye fundus images." *Computerized Medical Imaging and Graphics* 34, no. 3 (2010): 228-235.
- [6] W. Srisukkhom, P. Lepcha, M. A. Hossain, L. Zhang, R. Jiang, H. M. Lim, "A mobile enabled intelligent scheme to identify blood cancer for remote areas - cell membrane segmentation using marker controlled watershed segmentation phase." *7th International Conference on Software, Knowledge, Information Management and Applications*, (SKIMA 2013), Chiang Mai, Thailand, 104 - 114.
- [7] C. Sabanayagam, E. S. Tai, A. Shankar, J. Lee, C. Sun, and T. Y. Wong, "Retinal arteriolar narrowing increases the likelihood of chronic kidney disease in hypertension." *Journal of Hypertension* 27, no. 11 (2009): 2209-2217.
- [8] H. Rui, C. M. Queen, and G. Zouridakis, "Detection of Buruli ulcer disease: preliminary results with dermoscopic images on smart handheld devices." *Point-of-Care Healthcare Technologies (PHT)*, IEEE, 168-171. IEEE, 2013.
- [9] C.-N. Lee, Y.-T. Chu, L. Cheng, C.-C. Wu, and C.-Y. Yang, "Usage of smart mobile device at the telemedicine." *2011 International Conference on Machine Learning and Cybernetics (ICMLC)*, 2, 582-587. IEEE, 2011.
- [10] A. Sopharak, B. Uyyanonvara, S. Barman, and T. H. Williamson, "Automatic detection of diabetic retinopathy exudates from non-dilated retinal images using mathematical morphology methods." *Computerized Medical Imaging and Graphics* 32, no. 8 (2008): 720-727.
- [11] M. G. F. Eadgahi, and H. Pourreza, "Localization of hard exudates in retinal fundus image by mathematical morphology operations." *2nd International eConference on Computer and Knowledge Engineering (ICCKE)*, 185-189. IEEE, 2012.
- [12] D. Youssef, N. Solouma, A. El-dib, M. Mabrouk, and A.-B. Youssef, "New feature-based detection of blood vessels and exudates in color fundus images." *2nd International Conference on Image Processing Theory Tools and Applications (IPTA)*, 294-299. IEEE, 2010.
- [13] C. I. Sánchez, M. Niemeijer, M. S. A. Suttrop Schulten, M. Abrámoff, and B. Van Ginneken, "Improving hard exudate detection in retinal images through a combination of local and contextual information." *IEEE International Symposium on Biomedical Imaging: From Nano to Macro, 2010*, 5-8. IEEE, 2010.
- [14] S. Ravishankar, A. Jain, and A. Mittal, "Automated feature extraction for early detection of diabetic retinopathy in fundus images." *IEEE Conference on Computer Vision and Pattern Recognition (CVPR)*, 2009, 210-217. IEEE, 2009.
- [15] T. Kauppi, V. Kalesnykiene, J.-K. Joni-Kristian Kamarainen, L. Lensu, I. Sorri, A. Raninen, R. Voutilainen, H. Uusitalo, H. Kälviäinen, and J. Pietilä, "The DIARETDB1 diabetic retinopathy database and evaluation protocol." *BMVC*, 1-10. 2007.
- [16] M. Kirchner, and J. Fridrich, "On detection of median filtering in digital images." *IS&T/SPIE Electronic Imaging*, International Society for Optics and Photonics, 2010.
- [17] K. Vij, and Y. Singh, "Enhancement of images using histogram processing techniques", *International Journal Computational Technology Applications*, (2011), no 2, 309-313.
- [18] A. Sopharak, B. Uyyanonvara, and S. Barman, "Automatic exudate detection from non-dilated diabetic retinopathy retinal images using fuzzy c-means clustering." *Sensors* 9, no. 3 (2009): 2148-2161.
- [19] P. Maragos, and R. W. Schafer, "Morphological systems for multidimensional signal processing." *Proceedings of the IEEE* 78, no. 4 (1990): 690-710.
- [20] R. C. Gonzalez, R. E. Woods, S. L. Eddins "Morphological reconstruction from digital image processing using MATLAB", MATLAB, Digital Image Processing – Third Edition, Library of Congress Cataloging-in-Publication Data on File, 2008.
- [21] A. Bourouis, M. Feham, M. A. L. Hossain, Zhang, "An intelligent mobile based decision support system for retinal disease diagnosis. decision support systems". *Elsevier*, March 2014, 341-350.